



Case study

Heterakis gallinarum and *Histomonas meleagridis* in laying hens reared in cage system: A case report

Morales-Barrera J. Eduardo¹, Rocha-González Alexis¹, Fuentes-Cruz. B. Magnolia¹, Guillermo Tellez-Isaias², and Awad A. Shehata³

¹ Autonomous Metropolitan University, México City, México

² Gut Health LLC, Fayetteville, AR, USA

³ Structural Membrane Biochemistry, Bavarian NMR Center, Technical University of Munich (TUM), Garching, Germany



Abstract

In the present study, 108-week-old Hyline W-98 laying hens, reared in a cage system in a farm allocated in Tepatlán de Morelos Jalisco, México, showed cyanosis of the comb and wattles, and greenish-brown diarrhea. Macroscopic lesions revealed diffuse inflammation of the caecum with thinning walls and the presence of numerous small white worms of almost 2 cm, identified as *Heterakis gallinarum*. The liver was severely congested. Histopathological examination of the liver revealed the presence of necrosis and numerous forms of *Histomonas* trophozoites. Due to the unavailability of commercial vaccines and therapeutics against *H. meleagridis*, field surveillance in poultry is proviral to understanding the epidemiology and pathogenesis of *H. meleagridis* and identifying solutions for histomoniasis. Additionally, hence, the advantage of production in cages system is the control of parasitic infections; the subject of research is how birds were infested with *Heterakis gallinarum* and *Histomonas meleagridis* in this type of production.

Keywords: Parasites, *Heterakis gallinarum*, *Histomonas meleagridis*, layers

Article History:

Received: 9-Oct-2024

Accepted: 30-Oct-2024

*Corresponding author:

Morales-Barrera. J. Eduardo
jemorab@correo.xoc.uam.mx

Citation: Morales-Barrera, J. E., Rocha-González, A., Fuentes-Cruz, B. M., Tellez-Isaias, G., and Shehata, A. A. 2025. Findings of *Heterakis gallinarum* and *Histomonas meleagridis* in laying hens in cages with raised floors. Ger. J. Vet. Res. 5 (1): 1-7. <https://doi.org/10.51585/gjvr.2025.1.0114>

Introduction

Gastrointestinal parasites in laying hens are a common problem with high prevalence in production systems, affecting their performance, as they lead to loss of body weight, loss of blood and plasma proteins via the gastrointestinal tract and leads to alterations in protein metabolism, depression in the activity of intestinal enzymes and accompanied with diarrhea (Tellez et al., 2023). One of the internal parasites that affect the digestive tract of birds is *Heterakis gallinarum*, a genus of gastrointestinal nematode helminths. The *Heterakidae* family inhabits the caecum of several domestic and wild gallinaceous birds (Das, 2019). *Heterakis gallinarum* exerts a traumatic and mild irritating action on the caecal mucosa, where, in parallel, they exert an exploratory action by

feeding on tissue and tissue exudates (Beckmann, 2021).

Heterakis gallinarum acts as a vector for transmitting *Histomonas meleagridis*, an anaerobic protozoan parasite that causes histomoniasis, also known as enterohepatitis or enzootic typhlohepatitis. The eggs of the caecal worm can survive in the environment for three weeks while harboring *Histomonas*. However, earthworms and houseflies can also ingest these eggs and act as secondary vectors (paratenic hosts), as well as through feed and water contaminated with infective eggs (Marchiondo, 2019). *Heterakis gallinarum*, having a high persistence in the host, becomes important for the survival of *Histomonas meleagridis*, mainly affecting turkeys with lesions in the cecum and liver.

The mortality rate can reach up to 80%-100% in turkeys (Hess, 2020). After parasitizing and degrading the caecal tissue, histomonas migrate to the liver through the hepatic portal blood, causing pathognomonic hepatic lesions in the form of a target and caseous cecal nucleic. Although less common, it has also been shown that *Histomonas meleagridis* can infect areas such as the brain, pancreas, heart, lungs, kidneys, spleen, and bursa of Fabricius (Beer et al., 2022).

Histomoniasis can also occur in chickens, but the disease is not severe in chickens compared to turkeys (Mitra et al., 2018). The mortality in chickens can reach up to 10-20% (McDougald, 2005). However, it can cause more severe economic losses in chickens compared to turkeys due to the number of birds involved and the frequency of incidences. The separate rearing of poultry species is critical as chickens are considered partially resistant to histomonosis, frequently serving as asymptomatic carriers and reservoirs of *Histomonas meleagridis*-infected heterakid eggs (McDougald, 2005).

In the last decade, there has been an increase in research about histomonosis (Abd Elwahab et al., 2021). However, some epidemiologic aspects remain unanswered, such as risk factors associated with the transmission of histomonosis and the lack of a model of infection by horizontal transmission. The replication of horizontal transmission of histomonosis has not been consistent in many research groups in the last few years (Regmi et al., 2016). Currently, there are no available commercial vaccines against *Histomonas meleagridis*. Additionally, the efficacy of available therapeutics is inconsistent, and in some countries, there are no registered products. Therefore, biosecurity and surveillance studies of *Histomonas meleagridis* in chickens and turkeys are crucial for minimizing the transmission and better understanding of the disease epidemiology. In this study, *Heterakis gallinarum* and *Histomonas meleagridis* were detected in laying hens kept in cages with raised floors.

Case history

In 2024, during the late first molting period of 108-week-old Hyline W-98 laying hens, clinical signs of emaciation (Figure 1),

cyanosis in the comb and wattles, and greenish-brown diarrhea were reported. The flock size was 25,000 birds, reared in cages on a farm located in Tatiana de Morelos, Jalisco, Mexico. Hens had a history of vaccination against Newcastle (ND), infectious bronchitis (IB), infectious bursal disease (IBD), infectious laryngotracheitis (ILT), infectious coryza, avian encephalomyelitis (AE), and pox virus. Additionally, they were treated quarterly against ectoparasites. Upon inspection, lesions of chronic diffuse caecal inflammatory processes and thinning of the walls with the presence of nematodes were found, as well as severe congestion of the liver (Figure 2). Ceca and liver samples were collected for microscopic and histopathological examination.

Microscopic examination

Using a stereoscopic microscope, the nematode showed the typical morphological characteristics of *Heterakis gallinarum*. Nematodes were approximately 8-15 mm in length in the caecum, had an accentuated tail, and a widened esophagus forming a posterior bulb corresponding to the *Heterakis gallinarum* (Figure 3 A).

Histopathological examination

Samples of the liver preserved in 10% formalin were used for histopathological examination and stained with hematoxylin-eosin. Histological findings in liver tissue showed an inflammatory process with giant multinucleated cells, macrophages, epithelioid cells, lymphocytes, and around small clear areas with eosinophilic roundworms identified as *Histomonas meleagridis* trophozoites with extensive parenchymal necrotic areas (Figure 3 B, C, D)

Discussion

Although *Heterakis gallinarum* has a direct life cycle that does not require an intermediate host to be completed, it is generally believed that birds raised on high density have a higher risk of infestation (Cupo and Beckstead, 2019). The biological cycle of *Heterakis gallinarum* is illustrated in Figure 4. The presence of this parasite is practically non-existent in birds reared in cages.

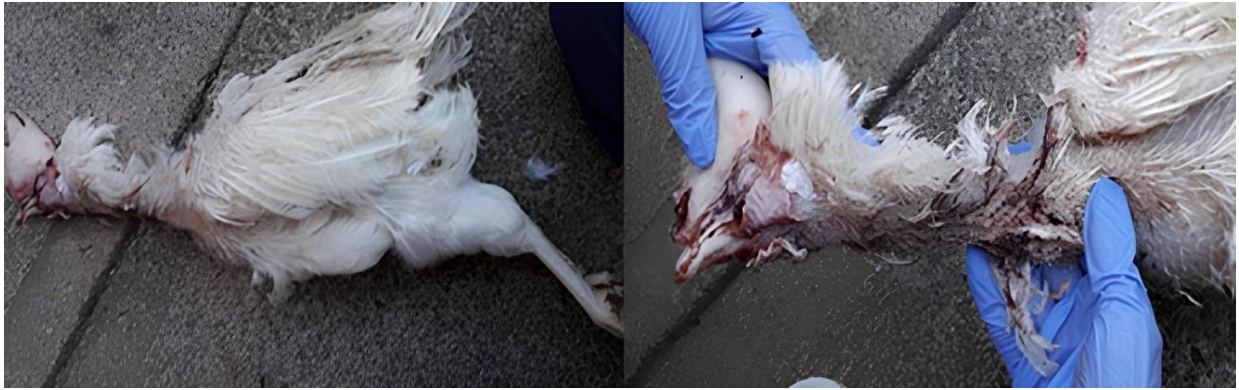

Figure 1: Body appearance of the birds with cachectic disease.

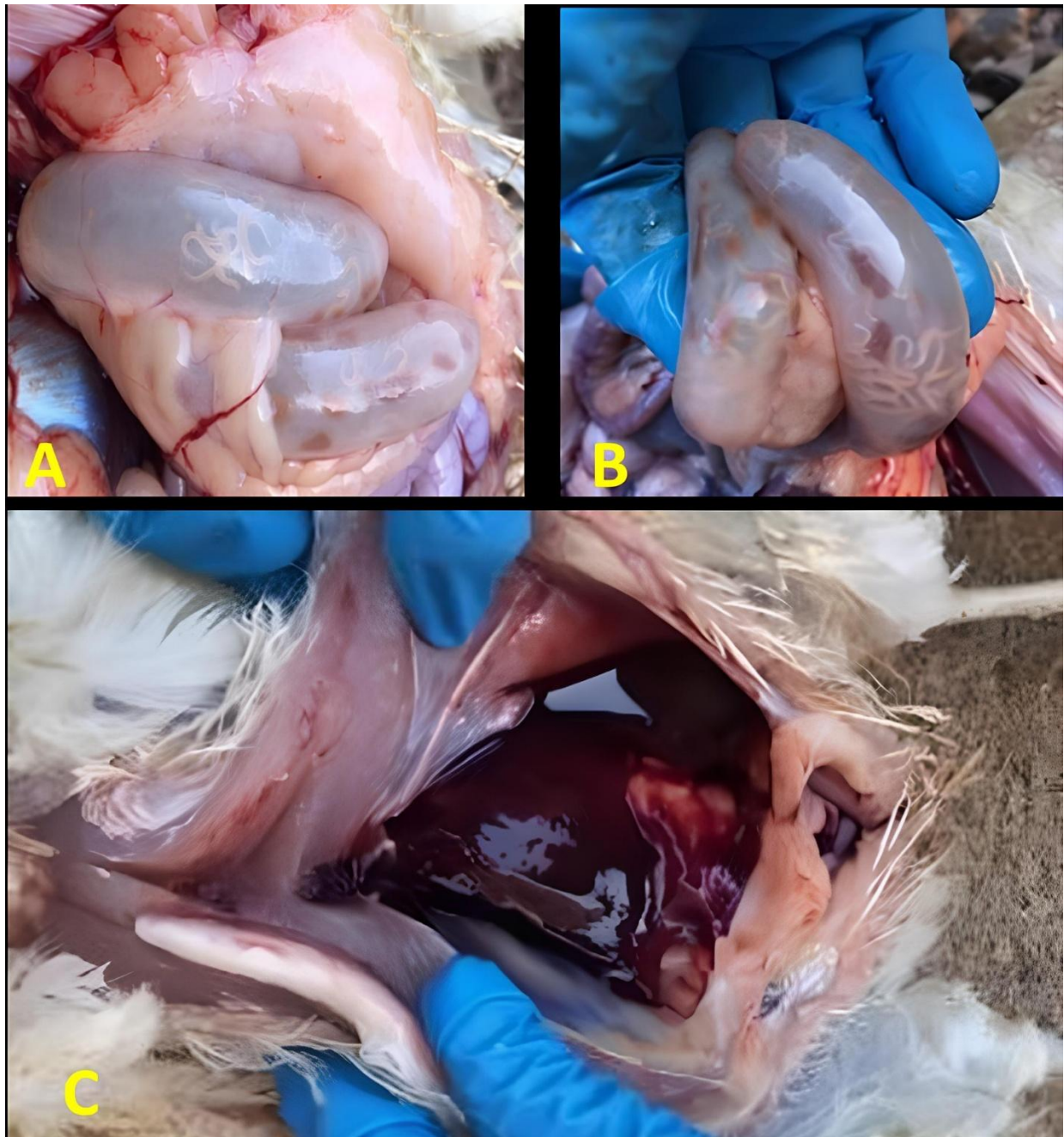


Figure 2: Macroscopic lesions with diffuse chronic inflammatory conditions, with thinning of the blind walls due to severe parasitosis by *Heterakis gallinarum* (A and B). Gross pathology of the liver in chickens naturally *Heterakis meleagridis*, showing severe congestion (C).

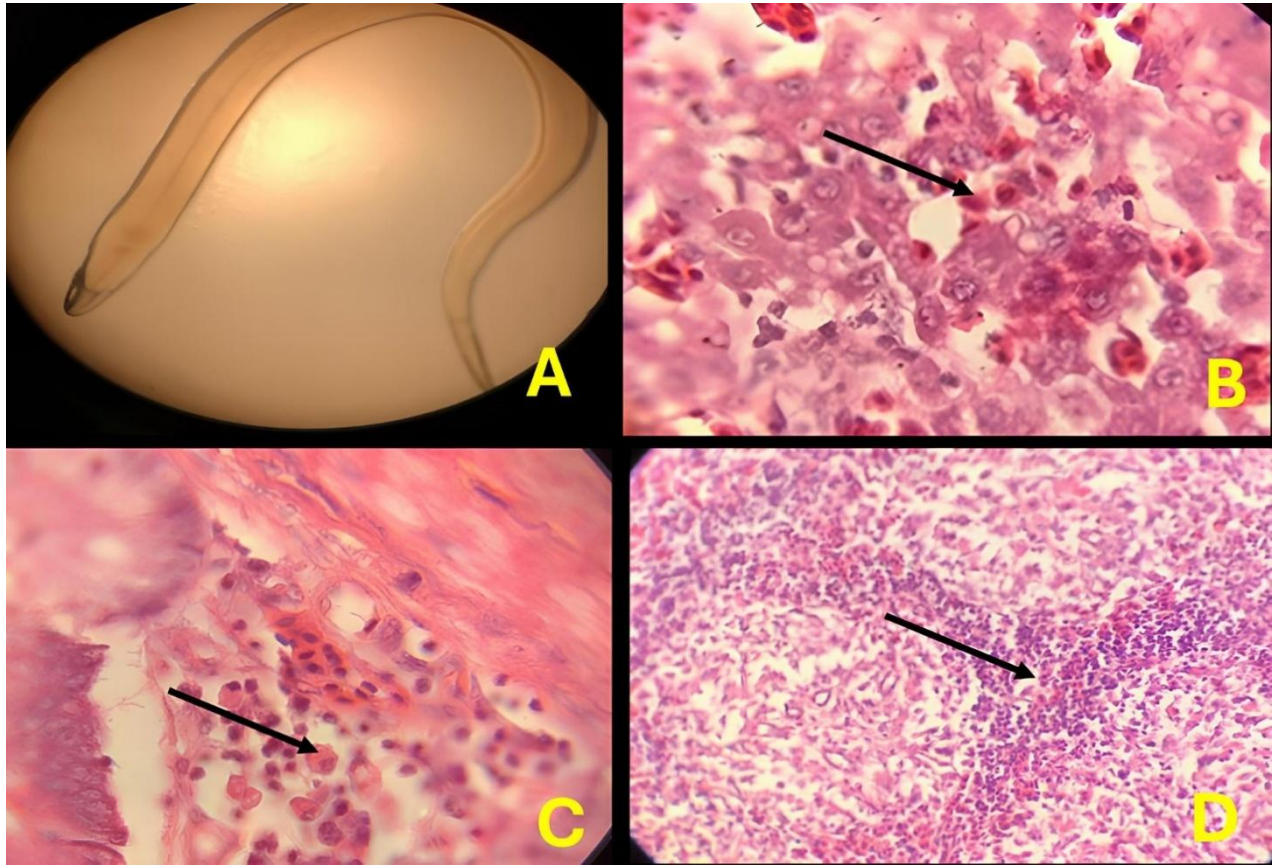


Figure 3: Microscopic and histopathological examination. (A) shows *Heterakis gallinarum* in the caecum, with an approximate length of 8-15 mm; the accentuated tail of the long, widening esophagus was observed at the stereoscopic microscope, forming a posterior bulb corresponding to *Heterakis gallinarum*. (B and C) histopathological examination of the liver, focal areas of necrosis containing numerous forms of trophozoites of *Histomonas meleagridis* (arrow), as shown by H&E stains; and (C) shows liver tissue with an inflammatory process with areas with eosinophilic roundworms identified as *Histomonas meleagridis* trophozoites (arrow).

However, in the literature, it has been reported that some vectors, such as the earthworm and house fly, can host their eggs during the infesting phase, as well as contaminated food and water, which birds have access to by ingesting (Jilo et al., 2022). In addition, their eggs serve as a vector for the protozoan parasite *Histomonas meleagridis*, which causes histomoniasis in birds and disease due to severe inflammation of the caecum and liver. The mortality rate of up to 90% in turkey flocks is high. Figure 5 shows the complex transmission of *Histomonas meleagridis*.

It is generally believed that birds raised in high stocking density on bedding have a greater risk of accumulating large amounts of nematodes. The eggs of this parasite are mostly very resistant to environmental conditions and release the protozoan in the caecum, where they multiply by simple bipartition. Female

worms deposit up to 900 eggs a day, which reach the outside with faeces and reach the liver via the bloodstream. Infectious L2 larvae develop in the environment within these eggs in about 7 to 70 days, depending on stocking density, humidity of the litter, and environmental temperature (2 to 4 weeks at 27°C) (Terra et al., 2023). The larvae hatch in the crop and gizzard but mostly in the small intestine. Then, they migrate to the caecum, where some invade the mucosa or remain in the crypts. The prepatent period is 24 to 36 days (Cupo and Beckstead, 2019). *Heterakis* spp. play a role in transmitting *Histomonas meleagridis*, which are unable to initiate the disease in the absence of caecal worms.

Histomoniasis is a frequent disease nowadays, causing drastic economic losses (Liebhart et al., 2010). The reason for this may be due to the withdrawal of several therapeutics that were used for controlling and preventing disease in the past. In

chickens, the cause of the disease is less severe, but it can cause lesions in the cecum and liver and a significant decrease in egg production (Tahseen, 2016; Terra, 2023). This study revealed gastrointestinal parasitosis caused by the nematode *Heterakis gallinarum*. Even though the chicken comes from an intensive production system in elevated cages, this type of parasitosis would not exist, possibly caused by the production conditions, the presence of fauna, and vectors such as the fly.

The control of parasitic diseases depends mostly on the accurate and timely diagnosis to establish the correct and effective prophylactic as well as therapeutic measures that allow for improving the profitability of the productions. Although histomoniasis is not a new disease, and multiple investigations have been conducted over the last century to understand this disease better, at present, multiple aspects of transmission and factors influencing disease outcomes are not fully understood. The complex dynamism between *Histomonas*

meleagridis, the host immune system, and the microbiota in the caeca and the litter makes prediction and understanding of the pathogenicity and transmission very difficult. Biosecurity measures to prevent exposure to *Histomonas meleagridis* or vectors of this protozoa are important to reduce histomoniasis incidence due to the absence of vaccines or approved drugs (Beer et al., 2020). In the early stages of the disease, one possible strategy for preventing outbreaks of histomoniasis is controlling the intermediate host *Heterakis gallinarum*, but with limitations. Control of intestinal parasites was done with Fenbendazole which is an approved antiparasitic for the treatment against *Heterakis* in turkeys and laying birds. Benzimidazole agents, such as Fenbendazole, are approved to control *Histomonas gallinarum* in chickens in the United States (Regmi et al., 2016). The implementation of fat-soluble vitamins A, E, D3, and K is a good practice since the absorption of fat-soluble vitamins decreases when intestinal diseases occur, such as histomoniasis.

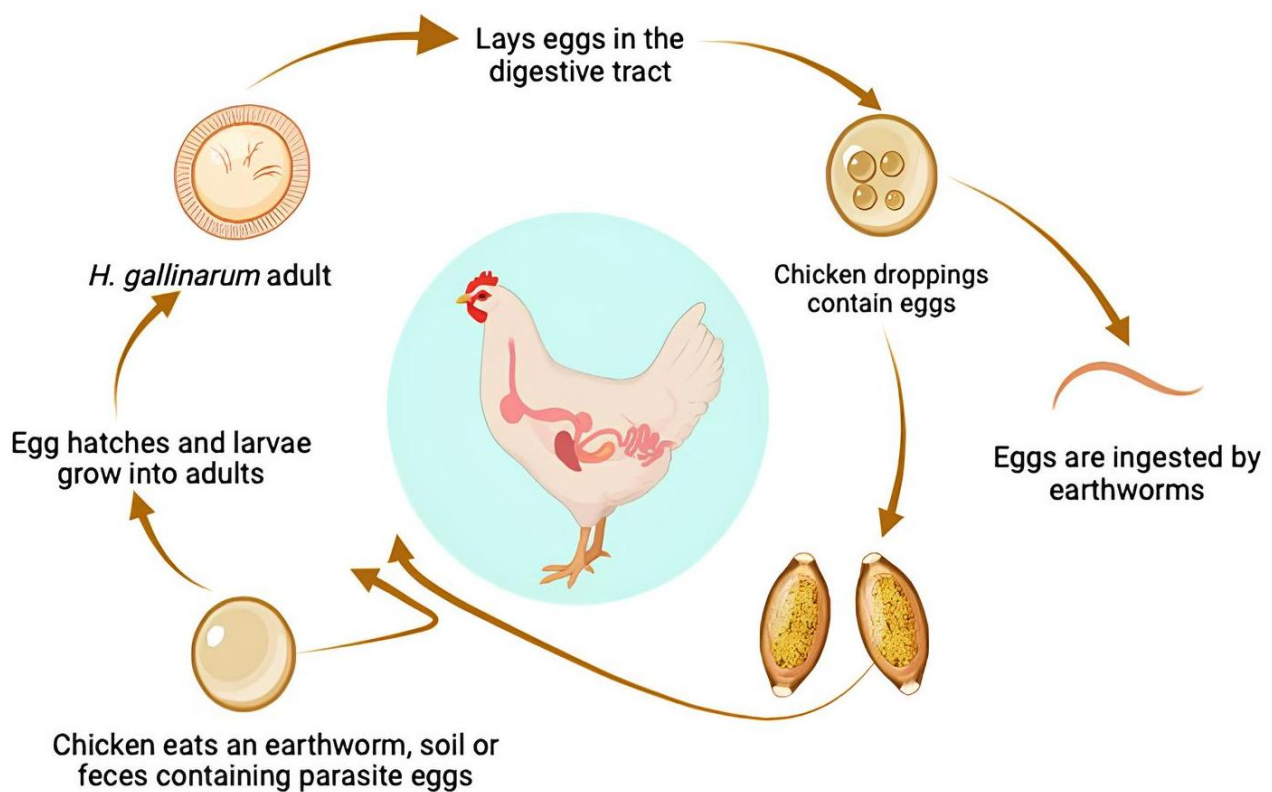


Figure 4: Biological cycle of *Heterakis gallinarum*. The larvae hatch in the crop and gizzard, but most of them in the small intestine and then migrate to the caecum, where some invade the mucosa and pass into the lymphatic tissue; others remain in the crypts or return to the lumen. The prepatent period is 24 to 36 days. (Created with BioRender.com).

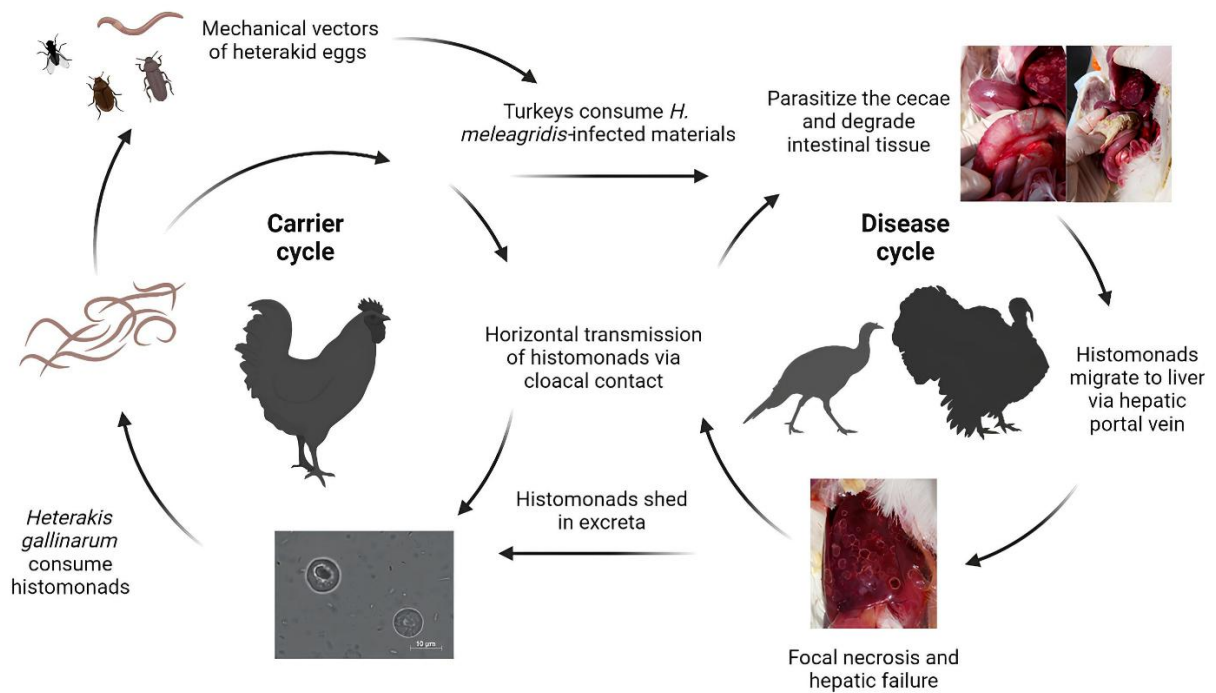


Figure 5: Complex transmission of *Histomonas meleagridis*. Histomonads can be consumed by *Heterakis gallinarum* and can be subsequently incorporated into the nematode ova. Carrier birds such as chickens can harbor the cecal worms and shed infected heterakid eggs into the environment. Earthworms, flies, and other invertebrates can serve as intermediate mechanical vectors of infected heterakid ova. Turkeys may ingest infected materials such as excreta or invertebrates contaminated with the protozoa. Once inside the intestine, the histomonads migrate to the ceca, replicating and degrading the cecal lining. Direct transmission can occur rapidly from turkeys to turkeys due to cloacal drinking and reverse peristalsis movement of materials into the vent region (Created with [BioRender.com](https://www.biorender.com)).

Conclusion and recommendations

It is important to monitor chicken flocks monthly and take faecal samples to determine the complete elimination of *Heterakis gallinarum* since it is an intermediate host of *Histomonas meleagridis*. Although histomoniasis is not a new disease, and several investigations have been carried out during the last century to understand this disease better, the complex dynamics between *Histomonas meleagridis*, *Heterakis*, the host immune system, and the microbiota in the caeca are the predisposing factors that must be treated in birds in elevated posture in cages, as well as carry out a deworming protocol for its prevention, control, breaking the biological cycle of the parasites and controlling flies.

Article Information

Funding. This research received no external funding.

Conflicts of Interest. The authors declare no conflict of interest.

Authors contribution. Conceptualization, M-B.J.E., and G.T-I.; Data curation, M-B.J.E., R-G.A., F-C.B.M, G.T-I. and A.A.S.; Formal analysis, M-B.J.E., R-G.A., F-C.B.M, G.T-I. and A.A.S.; Funding acquisition, M-B.J.E.; Investigation, C.H.V., and M.H.; Methodology, M-B.J.E., R.G.A., F.C.B.M, G.T-I. and A.A.S.; Project administration, M-B.J.E., and G.T-I.; Resources, M-B.J.E.; Supervision, M-B.J.E., G.T-I. and A.A.S.; Validation, M-B.J.E., G.T-I. and A.A.S.; Visualization, M-B.J.E., G.T-I. and A.A.S.; Writing—original draft, M-B.J.E., G.T-I. and A.A.S.; Writing – review and editing, M-B.J.E., G.T-I. and A.A.S.

Publisher's Note. The claims and data contained in this manuscript are solely those of the author(s) and do not represent those of the GMPC publisher, editors, or reviewers. GMPC publisher and the editors disclaim the responsibility for any injury to people or property resulting from the contents of this article.

References

- Abd El-Wahab, A, Visscher, C., Haider, W., Dimitri, R., 2021. A case study of histomoniasis in fattening turkeys identified in histopathological investigations. *German Journal of Veterinary Research* 1, 13–18. <https://doi.org/10.51585/gjvr.2021.3.0015>
- Beckham, J.F., Dormitorio, T., Oladipupo, S., Bethonico, M., Terra, Lawrence, K.S., et al., 2021. *Heterakis gallinarum* and *Histomonas meleagridis* DNA persists in chicken's houses years after depopulation. *Veterinary Parasitology* 298,109536. <https://doi.org/10.1016/j.vetpar.2021.109536>

- Beer, L.C., Petrone, V., Graham, B.H.B., Danielle, ellez, G. I., Voung, C.N., 2022. Histomonosis in poultry: A comprehensive review. *Frontiers in Veterinary Science* 9, 1–16. <https://doi.org/10.3389/fvets.2022.880738>
- Cupo, K.L., Beckstead, R.M., 2019. *Heretakis gallinarum* the cecal nematode of gallinaceous birds: A critical review. *Avian Diseases* 63, 381–388. <https://doi.org/10.1637/0005-2086-63.3.381>
- Das, G., Westermark, P.O, Gauly, M., 2019. Diurnal variation in egg excretion by *Heterakis gallinarum*. *Parasitology* 146, 206–212. <https://doi.org/10.1017/S0031182018001075>
- Hess, M., McDougald, L.R. 2020. Protozoal Infections. In *Diseases of Poultry*, 1223–1230. 14th ed. Hoboken, NJ, USA: Wiley-Blackwell.
- Jilo, S.A., Abadula, Teyib, A.T., Abdulhak, S.Z., Gobana, R.H., Hasan, L.A., et al., 2022. Review on epidemiology, pathogenesis, treatment, control, and prevention of gastrointestinal parasite of poultry. *International Journal of Veterinary Sciences and Animal Husbandry* 7, 26–34. <https://doi.org/10.22271/veterinary.2022.v7.i5a.439>
- Liebhart, D., Windisch, M., Hess, M., 2010. Oral vaccination of 1-day-old turkeys with in vitro attenuated *Histomonas meleagridis* protects against histomonosis and has no negative effect on performance. *Avian Pathology* 39, 399–403. <https://doi.org/10.1080/03079457.2010.506906>
- Marchiondo, A.A., Cruthers, L.R., Reinemeyer, C.R., 2019. Nematoda. In: *Paraciticide Screening* (Vol. 2, pp.135–335). USA: Academic Press.
- Terra, M.T., Macklin, K.S., Burleson, M., 2023. Mapping the poultry insectome in and around broiler breeder pullet farms identifies new potential Dipteran vectors of *Histomonas meleagridis*. *Parasites and Vectors* 16, 244. <https://doi.org/10.1186/s13071-023-05833-x>
- McDougald, LR., 2005. Blackhead disease (histomoniasis) in poultry: a critical review. *Avian Diseases* 49, 462–476. <https://doi.org/10.1637/7420-081005R.1>
- Mitra, T., Alem Kidane, F., Hess, M., Liebhart, D., 2018. Unraveling the immunity of poultry against the extracellular protozoan parasite *Histomonas meleagridis* is a cornerstone for vaccine development: A review. *Frontiers in Immunology* 9, 2518. <https://doi.org/10.3389/fimmu.2018.02518>
- Regmi, P.R., Shaw, A.L., Hungerford, L.L., Messenheimer, J.R., Zhou, T., Pillai, P., et al., 2016. Regulatory considerations for the approval of drugs against histomoniasis (blackhead disease) in turkeys, chickens, and game birds in the United States. *Avian Diseases* 60, 725–730. <https://doi.org/10.1637/11451-061516-Review.1>
- Tahseen, Abdul-Aziz, Fletcher, O., Barnes, H.J., 2016. *Avian histopathology*. Fourth edition. AAAP, American Association of Avian Pathologists, pp. 407.
- Tellez-Isaias, G., Eisenreich, W., Petrone-Garcia, V.M., Hernandez-Velasco, X., Castellanos-Huerta, I., Tellez Jr. G., et al., 2023. Effects of chronic stress and intestinal inflammation on commercial poultry health and performance: A review. *German Journal of Veterinary Research* 3, 38–57. <https://doi.org/10.51585/gjvr.2023.1.0051>
- Terra, M.T., Macklin, K.S., Burleson, M. Jeon, A., Beckmann, J.F., Hauck, R., 2023. Mapping the poultry insectome in and around broiler breeder pullet farms identifies new potential Dipteran vectors of *Histomonas meleagridis*. *Parasites and Vectors* 16, 244. <https://doi.org/10.1186/s13071-023-05833-x>