



Case Report

A case study of histomoniasis in fattening turkeys identified in histopathological investigations

Amr Abd El-Wahab^{1,2*}, Christian Visscher², Wolfram Haider^{3*} and Radko Dimitri^{4*}

¹ Department of Nutrition and Nutritional Deficiency Diseases, Faculty of Veterinary Medicine, Mansoura University, Mansoura 35516, Egypt

² Institute for Animal Nutrition, University of Veterinary Medicine Hannover, Foundation, Bischofsholer Damm 15, D-30173 Hannover, Germany

³ Institute for Animal Pathology, 13127 Berlin, Germany

⁴ Elanco Deutschland GmbH, 61352 Bad Homburg, Germany

This article is published in the special issue: Turkey Diseases, Production and Management

**Article History:**

Received: 29-Apr-2021

Accepted: 18-May-2021

***Corresponding author:**

Amr Abd El-Wahab

E-mail: amrwahab5@mans.edu.eg**Abstract**

Histomoniasis is a parasitic disease of poultry with worldwide prevalence, having significant negative impacts on infected turkey health and welfare. A total of 53,000 male fattening turkeys (British United Turkeys, BUT6) of 140-day-old were admitted to the slaughterhouse in central Ukraine. No clinical signs were reported in the turkeys during the production cycle. Slaughtering of the turkeys revealed enlargement of the livers, most of which had a greenish color with alterations in the hepatic tissues (fibrosis). No other gross lesions were noted in other organs of the slaughtered birds. Fresh liver tissues were submitted to the laboratory to measure the concentrations of lead, cadmium, copper, and zinc to detect possible intoxication and/or differential diagnosis. The concentrations of measured heavy metals in the affected liver tissues were within the recommended normal ranges. Histological examination revealed microscopically proliferative changes in liver sections in different turkeys. Suspected tissue sections were stained with Periodic Acid Schiff and found positive for *Histomonas meleagridis* trophozoites. Overall, macroscopical or microscopical examinations of turkey livers are essential to confirm infection with histomonads, even if the clinical signs are unapparent. As outbreaks of histomoniasis in turkey flocks are increasing approaches to prevent and treat histomoniasis are urgently needed.

Keywords: Histomoniasis, *Histomonas meleagridis*, black head disease, turkey, diagnosis

Citation: Abd El-Wahab, A, Visscher, C., Haider, W. and Dimitri, R. 2021. A case study of histomoniasis in fattening turkeys identified in histopathological investigations. Ger. J. Vet. Res. 1(3): 13-18. <https://doi.org/10.51585/gjvr.2021.3.0015>

Introduction

Histomoniasis (syn.: blackhead disease) was first described as infectious enterohepatitis in turkeys (Smith, 1895). Histomoniasis is a protozoan parasitic disease caused by *Histomonas meleagridis* (*H. meleagridis*) (McDougald, 2003). *H. meleagridis* (phylum *Parabasalia*, class *Tritrichomonadea*, order *Tritrichomonadida*, family *Dientamoebidae/Protrichomonadinae*) is an anaerobic protozoan parasite existing in either flagellated or amoeboid forms (Rüdiger et al., 2010). Histomoniasis is a widely spread protozoan disease globally. The transmission occurs principally via ingestion of embryonated eggs of the caecal nematode *Heterakis gallinarum* containing *H. meleagridis* trophozoites or by ingestion of earthworms that have ingested nematode eggs (McDougald,

2005; Rüdiger et al., 2010). However, it has been reported that direct lateral transmission of *H. meleagridis* in turkeys can occur from bird to bird in the total absence of caecal nematodes via “cloacal drinking” (Hu and McDougald, 2003; Hu et al., 2004).

Outbreaks of blackhead disease are often sporadic, and the mortality rate ranges from less than 10% up to 100%, mostly depending upon the route and dose of infection (Rüdiger et al., 2010; Gonder and Tilley, 2016). Although, some outbreaks have been found in commercial turkey production (Callait-Cardinal et al., 2007), very little information is available on free-range farms. However, birds can be highly exposed to *H. meleagridis* by field contamination (McDougald, 2005). The complicated interactions with caecal worms, earthworms, intestinal microflora and coccidia, enhance the

spread and pathogenicity of histomonas from one flock to another (McDougald, 2003). In the European Union (EU), the last therapeutic and prophylactic drugs against histomoniasis were banned in 1995 and 2003, respectively (Hafez and Hauck, 2006). The use of nitroimidazoles was forbidden by Commission Regulation No. 1798/95 (CEC, 1995), and later on, nifursol, the only available preventive drug against histomoniasis, was banned by Council Regulation No. 1756/2002 (CEC, 2002). Thereafter, several outbreaks of histomoniasis in turkey flocks occurred and led to considerable economic losses (Jones et al., 2020). Regarding anti-histomonas, it is clearly recommended not to use nitroimidazoles such as metronidazole or dimetridazole in food-producing birds (CAC, 2013). Arsenicals used to prevent histomoniasis have never been registered in the EU (EMA, 2009). In the USA, the application of nitrohetero cyclic compounds and arsenical nitarsones in food-producing birds is also not allowed (FDA, 2015a,b). Similar regulations that resulted in the loss of any treatment options against histomoniasis were adopted in other countries. Consequently, it can be predicted that the re-emergence of histomoniasis may become a severe problem in different countries (Liebhart et al., 2017). The control of histomoniasis is based on good hygienic measures at the farm level, using drugs that reduce the presence of caecal worms and other herbal products with variable results (Lotfi et al., 2012).

In turkeys, the clinical signs of histomoniasis include sulfur-colored diarrhea, anorexia, weakness, depression and weight loss. However, an infected flock may contain both ill and healthy birds (McDougald, 2005). In most cases, *H. meleagridis* produces lesions in the liver and caeca (McDougald, 2005). At necropsy, the liver is enlarged with yellow or grey saucer-shaped lesions. Sometimes the liver may appear green with white foci. The caeca are enlarged with a caseous or fibrinonecrotic core in the lumen with hemorrhage and might be found perforated and lead to secondary peritonitis. The caecal contents have a foul-smelling odor (Clark and Kimminau, 2017). Lesions in the liver, caeca, kidney and spleen were observed following oral inoculation of turkeys with embryonated eggs of the caecal nematode, *Heterakis gallinarum*, infected with histomonads (Malewitz et al., 1958).

The pathogenesis of histomoniasis starts with the colonization of the parasite in the caecum, leading to severe inflammation and necrosis. Afterward, the parasite reaches the liver via portal veins, causing inflammation and damage in different parts of liver tissue. In the final stage, the disease may become systemic when the infections spread to various organs of the host (Grabensteiner et al., 2006). A presumptive diagnosis of blackhead disease can be made based on clinical signs, mortality rate and gross lesions (Clark and Kimminau, 2017). At necropsy, the characteristic bulls-eye-like liver lesions and caecal lesions (cheesy caseous cores, inflammation of the serosal surface and occasional ulceration) are very indicative. However, a diagnosis should be confirmed by histopathology (Clark

and Kimminau, 2017). Against this background, in the current case study, we describe gross and microscopic lesions of the liver observed in naturally infected male fattening turkey flocks with histomoniasis.

Materials and Methods

Case history

A total of 53,000 male fattening turkeys (British United Turkeys, BUT6), 140-day-old, were admitted to a slaughterhouse in central Ukraine. The turkeys were reared in seven houses on the farm of only male birds according to the general standard practices of fattening turkeys. The stocking density was generally about 58 kg/m². The case history did not include any abnormal signs (such as dehydration, depression, sulphur-colored droppings, reluctance to move and weight loss). Moreover, there was no high and/or massive mortality rate mentioned. However, it was reported that there were earthworms on the affected farm. Furthermore, many cases of *Escherichia coli* (*E. coli*) infection were reported in the birds during the production cycle and were treated with commercial antibiotics against *E. coli* as Biocillin[®], amoxicillin-trihydrate 1000 mg, bela-pharm GmbH Co.KG, Germany or Tylo-Suscit[®], tylosin tartrate 1000 mg, bela-pharm GmbH Co.KG, Germany.

Histopathological examination

The tested livers were collected from several houses at the same day of slaughtering. All rejected livers from the slaughtered birds were weighted. Sections of the liver (n = 9 samples) were collected, then fixed in 10% neutral buffered formalin, routinely processed and embedded in paraffin blocks. Sections 2 mm thick were cut, mounted on glass slides, stained with hematoxylin and eosin using standard protocols, and examined by light microscopy. Selected tissues were also stained with Periodic Acid Schiff (PAS) to identify histomonads.

Heavy metals analysis

Some of the fresh liver tissues were submitted to the laboratory to measure the concentrations of lead, cadmium, copper and zinc to prove possible intoxication and/or differential diagnosis. The analyses were performed in the center of veterinary diagnostics, Kiev, Ukraine. The determination of lead, cadmium, copper and zinc levels was done according to GOST 30178-96, GOST 30178-96, GOST 27995-88, and GOST 27996-88, respectively.

Results

Gross pathology

Visual monitoring revealed that approximately 20% of birds were mild to moderately emaciated and had liver lesions with varying degrees of severity. The livers were enlarged, and ulcerated lesions with circular depressions had formed on the surface. The lesions had a greenish color in the center, the peripheral edges were uplifted, and they had a unique crater-like shape (Figure 1). The weight of the rejected livers varied from 60

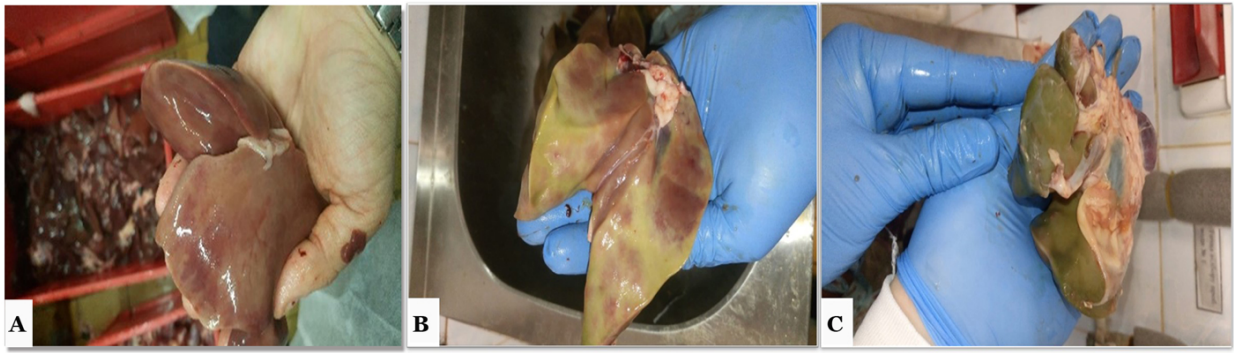


Figure 1: Gross lesions in liver showing characteristic hepatomegaly (A) with greenish color and fibrosis (B&C).

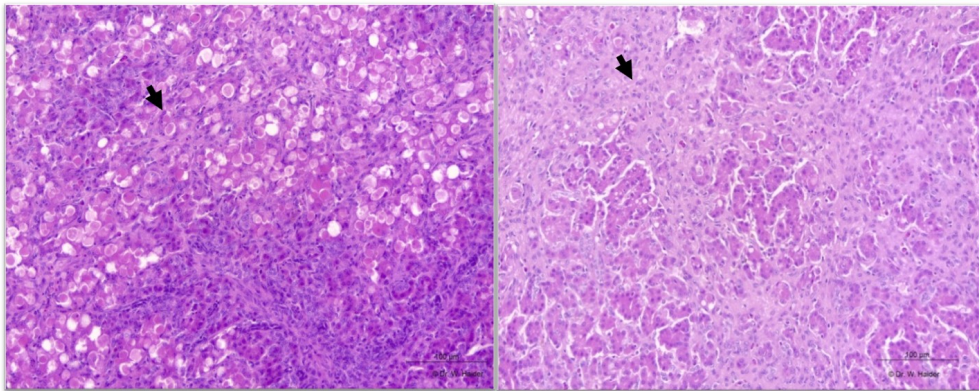


Figure 2: Abundant intra-lesional protozoal trophozoites showing PAS-positive reaction with central dark nuclei "arrows" (bar = 100 m).

to 80 g from approximately 1500 slaughtered turkeys daily. However, the caeca of the slaughtered birds were macroscopically normal.

Histopathological examination

In all cases, the examined livers had varying degrees of fibrosis. In some sections, the fibrosis covered a larger area and led to the detachment of pseudo-lobules. Mostly in the surrounding of fibrotic areas, low to high numbers of trophozoites of *H. meleagridis* were found in the liver tissue. Within these lesions, there were multiple extracellular and intra-histiocytic, round, PAS-positive protozoal trophozoites with central dark nuclei (Figure 2). Hepatic necrosis was not observed, but there was a possibility that they were already scarred. Inflammation was also no longer visible. Within some of the livers, there was moderate to severe dilatation of the bile ducts, some of which were proliferative and surrounded by severe granulomatous inflammation. A few bile ducts contained histomonads mixed with inflammatory debris. In cut sections, the hepatocytes showed a marked accumulation of fat, and occasionally hepatic icterus was also visible. No significant changes were observed in other organs. No eggs from trematodes, cestodes, nematodes or coccidial oocysts were found in the small intestines and caecal contents during conventional parasitic examinations.

Chemical analysis

The chemical analysis of some heavy metals in the rejected livers is presented in Table 1. The data revealed

that the concentrations of lead, cadmium, copper and zinc were about <0.07, 0.17, 5.31 and 24.6 mg/kg, respectively.

Discussion

Histomoniasis outbreaks in turkeys are commonly sporadic and accompanied by a high mortality rate (Gonder and Tilley, 2016). There is some evidence that young turkeys are thought to be more susceptible to infection with *H. meleagridis*, but mature turkey flocks could have severe disease (Lund and Chute, 1972). It is well known that male turkeys are more susceptible to *H. meleagridis* than female birds (McDougald, 2003). The mortality rate recorded in the present investigation was low since the mortality rate associated with histomoniasis ranges typically between 10% to 100% in natural outbreaks and experimental infections, respectively (McDougald, 2003). Economic losses in the turkey flocks resulted from reduced growth with increased condemnation rates as high as 20% (Senties-Cue et al., 2009). There is some evidence suggesting that different genotypes of *H. meleagridis* isolates differ in their virulence to chickens and turkeys (van der Heijden et al., 2006). Also, concurrent infections with bacteria, parasites and viruses have been known to exacerbate the problem contributing to an increase in the mortality rate (Hu and McDougald, 2002; McDougald, 2003). In the present case there was no evidence of coccidia, ascarids or *Heterakis gallinarum* infections in

Table 1: Analyzed contents of some heavy metals in the affected livers on fresh matter basis.

Parameter	Value (mg/kg)
Lead	0.07
Cadmium	0.17
Copper	5.31
Zinc	24.6

any of the examined birds. However, these parasites have been suggested as contributory factors to the increased mortality rate associated with blackhead disease in turkeys (Hu and McDougald, 2002; McDougald, 2003).

In our case study, the source of histomoniasis is unknown. However, earthworms were observed on the investigated farm, while *Heterakis gallinarum* was not detected microscopically. According to Hauck et al. (2010), insects or flies may serve as vectors. It is well established that the main route of histomonas infection is by ingestion of the embryonated eggs of the caecal worm *Heterakis gallinarum* (McDougald, 2005). Moreover, the trophozoites of *H. meleagridis* possess only a low tenacity (Lotfi et al., 2012). Thus, eggs of the nematode *Heterakis gallinarum* containing stages of *H. meleagridis* are regarded as a very important vector (McDougald, 2005). House-to-house/farm-to-farm transmission is hypothesized to occur via ingestion of infected *Heterakis gallinarum* eggs (Hess and McDougald, 2013). Additionally, contaminated water, fresh fecal matter, or both could play a role in transmitting the parasite within and among poultry houses (Lotfi et al., 2012).

Interestingly, no clinical signs of histomoniasis were observed in the flock. Also, it is worth mentioning that the birds were treated for *E. coli* with antibiotics during the production cycle. Using these antibiotics could have an indirect effect on reducing the clinical signs of histomoniasis in turkeys. However, several antibiotics, e.g., penicillin, chlortetracycline, tylosin and sarafloxacin, were tested with no effect on histomonads (Hu and McDougald, 2002). A positive effect of paromomycin, an aminoglycoside antibiotic, was already reported, with a link between the dose and the efficacy of the substance (Hafez et al., 2010; van der Heijden et al., 2011). Additionally, anticoccidials had no effect *in-vivo*, even though nicarbazin could reduce the liver lesions when broilers were co-infected with *Eimeria tenella* and *H. meleagridis* (Hu and McDougald, 2002). From the previous studies, it could be concluded that there is currently no product available that is likely to be licensed in the near future to treat histomoniasis. Histostat[®] (nitarson) and Histobloc[®] (paromomycin) offer prophylactic activity, but concerns were raised with regard to the ecological and consumer safety of such products (Hess et al., 2015).

The gross lesions found in the liver were similar to those reported previously (McDougald, 2003). The hepatic lesions in all likelihood, represent tissue reac-

tions at various stages of infection. The initial lesion probably started as a small amount of necrosis and inflammation that coalesced to form larger nodules resembling lymphoma (Senties-Cue et al., 2009). In later stages, extensive necrosis of hepatocytes resulted in a collapse of the parenchyma, the latter producing typical saucer-shaped foci in the liver. There was a good correlation between gross and microscopic lesions for the liver, as previously confirmed by Senties-Cue et al. (2009). In current case study, there have been no reports of lesions other than in the liver in natural outbreaks of histomoniasis in turkeys. However, Senties-Cue et al. (2009) found both gross and microscopic lesions in the kidney, bursa of Fabricius, lung, pancreas, proventriculus and spleen in addition to the characteristic lesions of histomoniasis in the liver and caeca of commercial turkeys. The reasons for such a discrepancy are unknown. The mechanisms by which *H. meleagridis* gained access to different organs are still as yet undetermined, but it is most probably through the invasion of the vascular system (Clarkson, 1961). However, no information on the clinical course of cases under investigation was available, except the fact that the hepatic lesions were severe at the time of slaughter.

Histopathological studies have shown that many individual and clustered histomonads are visible, confirming the results of McDougald (2005). Special staining, such as PAS, was helpful in identifying many histomonads. Nevertheless, there were many histomonads that did not stain by PAS (Senties-Cue et al., 2009). The reason for this is unknown, though autolysis can influence staining. However, the tissues examined in this study were not autolytic. One possible explanation for this discrepancy could be the different developmental stages of histomonads, where some stages stained while others not stained with PAS (Senties-Cue et al., 2009). The gross and histological changes in the current cases were consistent among the samples and were compatible with previous descriptions of histomoniasis in other gallinaceous birds (McDougald, 2005; Hauck and Hafez, 2013). There was no evidence of *Heterakis gallinarum* infestation in any of the examined cases in this study, which is also consistent with previous experimental infections (Lund and Chute, 1972).

It is worth mentioning that all the tested tissues were found to contain lower lead levels than the maximum permitted lead concentration (0.1 mg/kg) in poultry set by the FAO/WHO Codex Alimentarius and European Commission (European Commission, 2006). Lead is one of the potentially toxic contaminants in

the environmental samples, and its higher level in feedstuffs is of particular concern (EFSA, 2010). Cadmium levels in the tested samples were reported to be well below the permissible limits of 0.5 mg/kg known from the EU (European Commission, 2006). The level of copper detected in this study was found to be similar to the reported values in the literature (EFSA, 2016). The average concentration of copper in liver samples was lower than the maximum permissible limit (10 mg/kg) in poultry set by the FAO/WHO Codex Alimentarius and European Commission (European Commission, 2006). Copper is considered vital and toxic (at higher levels) for the biological systems (EFSA, 2016). The average zinc level in the tested samples was lower (24.6 mg/kg) than the permissible zinc limit of 40 mg/kg (European Commission, 2006). Zinc is a relatively non-toxic element. However, long-term exposure to an elevated amount may produce toxic effects (EFSA, 2014).

Conclusions

Histomoniasis is a re-emerging disease in various countries without licensed to use effective chemotherapeutics. Examination either macroscopically or microscopically of turkey livers is essential to confirm infection with histomonads. Overall, all preventative management measures should be strictly applied to prevent the infection of histomonads in turkey flocks. Additionally, different strategies including the use of chemicals, plant-derived compounds or vaccination still need to be investigated to prevent the occurrence of the disease.

Article Information

Funding. This research received no external funding

Conflict of Interest. The authors declare no conflict of interest.

Acknowledgments. We would like to thank Frances Sherwood-Brock for proof reading the manuscript to ensure correct English.

References

CAC, 2013. Joint FAO/WHO food standard program codex alimentarius commission, residues of veterinary drugs in food. (Codex Classification of Foods and Animal Feeds) .

Callait-Cardinal, M.P., Leroux, S., Venereau, E., Chauve, C.M., Le Pottier, G., Zenner, L., 2007. Incidence of histomonosis in turkeys in france since the bans of dimetridazole and nifursol. *Veterinary Record* 161, 581–5. [10.1136/vr.161.17.581](#).

CEC, 1995. Commission regulation (EC) No 1798/95 of July 25, 1995 amending Annex IV to Council Regulation (EEC) no 2377/90 laying down a community procedure for the establishment of maximum residue limits of veterinary medicinal products in foodstuffs of animal origin. *Official Journal*, L174, 20–21 .

CEC, 2002. Council regulation (EC) No 1756/2002 of 23 September 2002. amending directive 70/524/EEC concerning additives in feedingstuffs as regards withdrawal of the authorisation of an additive and amending commission regulation (EC) No 2430/1999. *Official Journal*, L174, 20–21 .

Clark, S., Kimminau, E., 2017. Critical review: Future control of blackhead disease (histomoniasis) in poultry. *Avian Diseases* 61, 281–288. [10.1637/11593-012517-ReviewR](#).

Clarkson, M.J., 1961. The blood supply of the liver of the turkey and the anatomy of the biliary tract with reference to infection with *Histomonas meleagridis*. *Research in Veterinary Science* 2, 259–264. [10.1016/S0034-5288\(18\)34957-9](#).

EFSA, 2010. Scientific opinion of the panel on contaminants in the food chain. lead in food. *EFSA Journal* (published on 22 March 2013, replaces version 2010) 8, 1570.

EFSA, 2014. Panel on dietetic products nutrition and allergies. scientific opinion on dietary reference values for zinc. *EFSA Journal* 12, 3844.

EFSA, 2016. Panel on additives and products or substances used in animal feed (FEEDAP). revision of the currently authorised maximum copper content in complete feed. *EFSA Journal* 14, e04563.

EMA, 2009. European Medicines Agency. status of MRL procedures. MRL assessments in the context of Council Regulations (EEC) No 2377/90. EMEA/CVMP/765/99- Rev.23, 1–19 .

European Commission, 2006. Commission regulation (EC) No 1881/2006 of 19 December 2006 setting maximum levels for certain contaminants in foodstuffs. *Official Journal of the European Union* 364, 5–24.

FDA, 2015a. FDA announces pending withdrawal of approval of nitarson. Rockville, MD: FDA, Center for Veterinary Medicine .

FDA, 2015b. Title 21. food and drugs, chapter i-food and drug administration, Department of Health and Human Services, subchapter E-animal drugs, feeds, and related products, part 530 – extralabel drug use in animals, subpart e-safe levels for extralabel use of drugs in animals and drugs prohibited from extralabel use in animals. 530.41. Code of Federal Regulations 6 (revised as of April 1, 2015).

Gonder, E., Tilley, B., 2016. A recurrence of blackhead in young turkey breeder toms in a house that had experienced blackhead many years previously. *Proc. AAAP/AVMA Blackhead Mini-symposium* , 16.

Grabensteiner, E., Liebhart, D., Weissenböck, H., Hess, M., 2006. Broad dissemination of *Histomonas meleagridis* determined by the detection of nucleic acid in different organs after experimental infection of turkeys and specified pathogen-free chickens using a mono-eukaryotic culture of the parasite. *Parasitology International* 55, 317–22. [10.1016/j.parint.2006.07.004](#).

Hafez, H.M., Hauck, R., 2006. Efficacy of a herbal product against *Histomonas meleagridis* after experimental infection of turkey poults. *Archives of Animal Nutrition* 60, 436–42. [10.1080/17450390600884500](#).

Hafez, H.M., Hauck, R., Gad, W., De Gussem, K., Lotfi, A., 2010. Pilot study on the efficacy of paromomycin as a histomonostatic feed additive in turkey poults experimentally infected with *Histomonas meleagridis*. *Archives of animal nutrition* 64, 77–84. [10.1080/17450390903478851](#).

Hauck, R., Balczulat, S., Hafez, H.M., 2010. Detection of DNA of *histomonas meleagridis* and *Tetratrichomonas gallinarum* in german poultry flocks between 2004 and 2008. *Avian Diseases* 54, 1021–1025. [10.1637/9261-012910-Reg.1](#).

Hauck, R., Hafez, H.M., 2013. Experimental infections with the protozoan parasite *Histomonas meleagridis*: a review. *Parasitology Research* 112, 19–34. [10.1007/s00436-012-3190-5](#).

- Hess, M., Liebhart, D., Bilic, I., Ganas, P., 2015. *Histomonas meleagridis*-new insights into an old pathogen. *Vet Parasitol* 208, 67–76. [10.1016/j.vetpar.2014.12.018](https://doi.org/10.1016/j.vetpar.2014.12.018).
- Hess, M.M., McDougald, L.R., 2013. Histomoniasis (blackhead) and other protozoan diseases of the intestinal tract, in: Swayne, D.E.G., John, R., McDougald, L.R., Nolan, L.K., Suarez, D.L., Nair, V. (Eds.), *Diseases of Poultry*. 13 ed., pp. 1172–1178.
- Hu, J., Fuller, L., McDougald, L.R., 2004. Infection of turkeys with *Histomonas meleagridis* by the cloacal drop method. *Avian Diseases* 48, 746–50. [10.1637/7152](https://doi.org/10.1637/7152).
- Hu, J., McDougald, L.R., 2002. Effect of anticoccidials and antibiotics on the control of blackhead disease in broiler breeder pullets. *Journal of Applied Poultry Research* 11, 351–357. [10.1093/japr/11.4.351](https://doi.org/10.1093/japr/11.4.351).
- Hu, J., McDougald, L.R., 2003. Direct lateral transmission of *Histomonas meleagridis* in turkeys. *Avian Diseases* 47, 489–92. [10.1637/0005-2086\(2003\)047\[0489:DLTOHM\]2.0.CO;2](https://doi.org/10.1637/0005-2086(2003)047[0489:DLTOHM]2.0.CO;2).
- Jones, R., Rives, D., Fletcher, O., Martin, M., 2020. Histomoniasis outbreaks in commercial turkeys in the southeastern United States: Proximity of broiler breeder farms as a potential risk factor in disease development. *Journal of Applied Poultry Research* 29, 496–501. [10.1016/j.japr.2019.12.006](https://doi.org/10.1016/j.japr.2019.12.006).
- Liebhart, D., Ganas, P., Sulejmanovic, T., Hess, M., 2017. Histomoniasis in poultry: previous and current strategies for prevention and therapy. *Avian Pathology* 46, 1–18. [10.1080/03079457.2016.1229458](https://doi.org/10.1080/03079457.2016.1229458).
- Lotfi, A.R., Abdelwhab, E.M., Hafez, H.M., 2012. Persistence of *Histomonas meleagridis* in or on materials used in poultry houses. *Avian Diseases* 56, 224–6. [10.1637/9519-090910-ResNote.1](https://doi.org/10.1637/9519-090910-ResNote.1).
- Lund, E.E., Chute, A.M., 1972. Heterakis and *Histomonas* infections in young peafowl, compared to such infections in pheasants, chickens, and turkeys. *Journal of Wildlife Diseases* 8, 352–8. [10.7589/0090-3558-8.4.352](https://doi.org/10.7589/0090-3558-8.4.352).
- Malewitz, T.D., Runnells, R.A., Calhoun, M.L., 1958. The pathology of experimentally produced histomoniasis in turkeys. *American Journal of Veterinary Research* 19, 181–5. URL: <https://www.ncbi.nlm.nih.gov/pubmed/13498258>.
- McDougald, L.R., 2003. Other protozoan diseases of the intestinal tract, in: Saif, Y.M., Barnes, H.J., Glisson, J.R., Fadly, A.M., McDougald, L.R., Swayne, D.E.G. (Eds.), *Diseases of Poultry*. 11 ed., pp. 1001–1006.
- McDougald, L.R., 2005. Blackhead disease (histomoniasis) in poultry: a critical review. *Avian Diseases* 49, 462–76. [10.1637/7420-081005R.1](https://doi.org/10.1637/7420-081005R.1).
- Rüdiger, H., Stefanie, B., Hafez, M.H., 2010. Detection of dna of *Histomonas meleagridis* and *Tetratrichomonas gallinarum* in German poultry flocks between 2004 and 2008. *Avian Diseases* 54, 1021–1025. [10.1637/9261-012910-Reg.1](https://doi.org/10.1637/9261-012910-Reg.1).
- Senties-Cue, G., Chin, R.P., Shivaprasad, H.L., 2009. Systemic histomoniasis associated with high mortality and unusual lesions in the bursa of Fabricius, kidneys, and lungs in commercial turkeys. *Avian Diseases* 53, 231–8. [10.1637/8363-051508-Reg.1](https://doi.org/10.1637/8363-051508-Reg.1).
- Smith, T., 1895. An infectious disease among turkeys caused by protozoa (infectious entero-hepatitis). U. S. Department of Agriculture, Bureau of Animal Industry Bulletin 8, 3–27.
- van der Heijden, H.M., De Gussem, K., Landman, W.J., 2011. Assessment of the antihistomonal effect of paromomycin and tiamulin. *Tijdschr Diergeneeskd* 136, 410–6. URL: <https://www.ncbi.nlm.nih.gov/pubmed/21699092>.
- van der Heijden, H.M., Landman, W.J., Greve, S., Peek, R., 2006. Genotyping of *Histomonas meleagridis* isolates based on Internal Transcribed Spacer-1 sequences. *Avian Pathology* 35, 330–4. [10.1080/03079450600815499](https://doi.org/10.1080/03079450600815499).